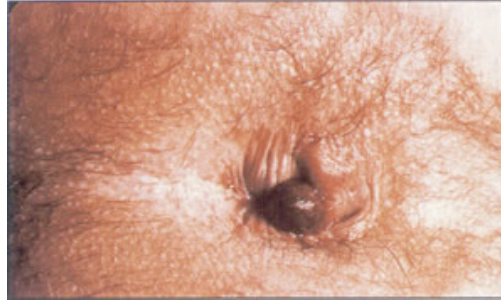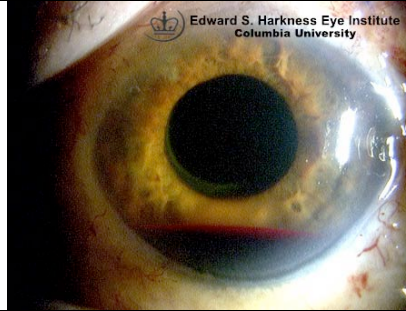


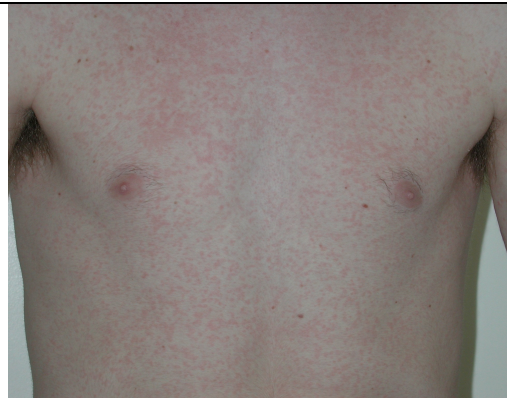40 year old man presents with 6h history of sudden onset of severe stabbing pain in his perianal region.  
What is the diagnosis?  
1point  
How would you treat it? 1 point



This man was hit in the eye yesterday. What is the diagnosis? 1point  
What grade is it?  
1point



This 18 year old young man was started yesterday on amoxicillin for ? tonsillitis.  
What is the true diagnosis? 1 point  
What caused the rash? 1 point



This 4 day old bay was brought in by his 17 year old mum concerned about the rash. He was a Full Term Baby, Normal Vaginal Delivery, being breast fed. Apyrexial, good appetite, sleeping well etc.  
What is the diagnosis? 1 point  
What is the treatment? 1 point

