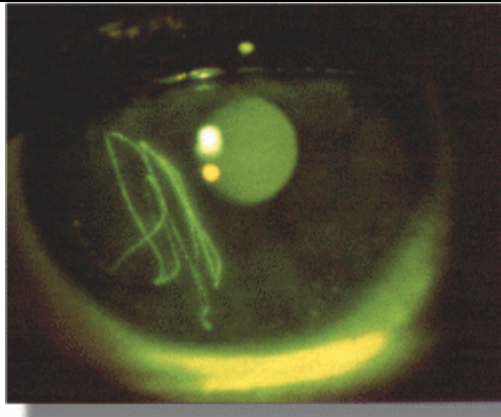
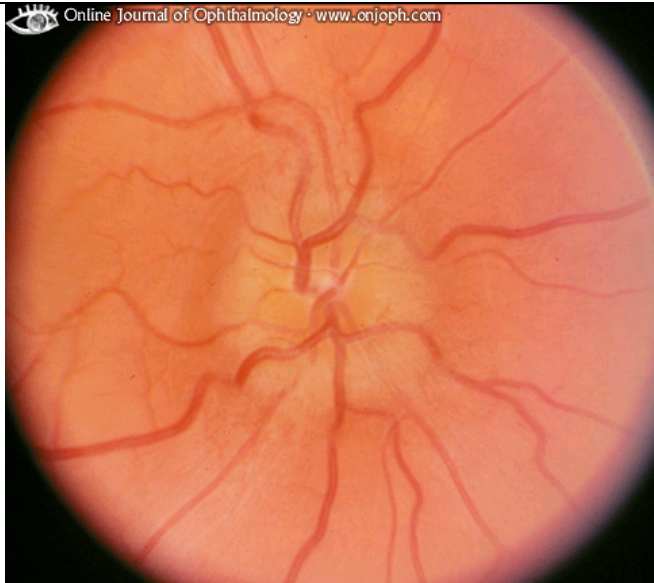


Pt is complaining of a foreign body sensation in his eye.
What is the most likely diagnosis?
1 point



Subtarsal foreign body- multiple vertical scratches

A 24 year old woman comes in to A&E c/o painful L eye. Pain gets worse on movement and she thinks she can't see very well out of the eye. There is no H/O trauma and slit lamp examination is unremarkable. Fundoscopy shown on the R- what does it show? 1 point
List 3 other tests which should be performed in A&E to help reach the diagnosis. 3 points
What is the diagnosis and what is the treatment? 2 points



Optic disc oedema

Visual acuity- often reduced, afferent pupillary defect- often present and red desaturation test- usually positive

Optic neuritis- Rx either with IV steroids or conservative, oral steroids have a worsening outcome (-1/2 for that)

A 60 year old man is brought in by his daughter. He had been unwell recently and seems to have lost some weight and has been feeling increasingly tired and his GP has started him on immigra a couple of weeks ago. Today the pt noticed that he could not see out of his L eye. What is the diagnosis? 1 point

What 2 blood tests would you perform to confirm it? 1 point

How would you treat it? 1 point

Ischaemic optic neuropathy due to Giant Cell Arteritis

ESR and CRP

Steroids- IV hydrocort or methyl pred