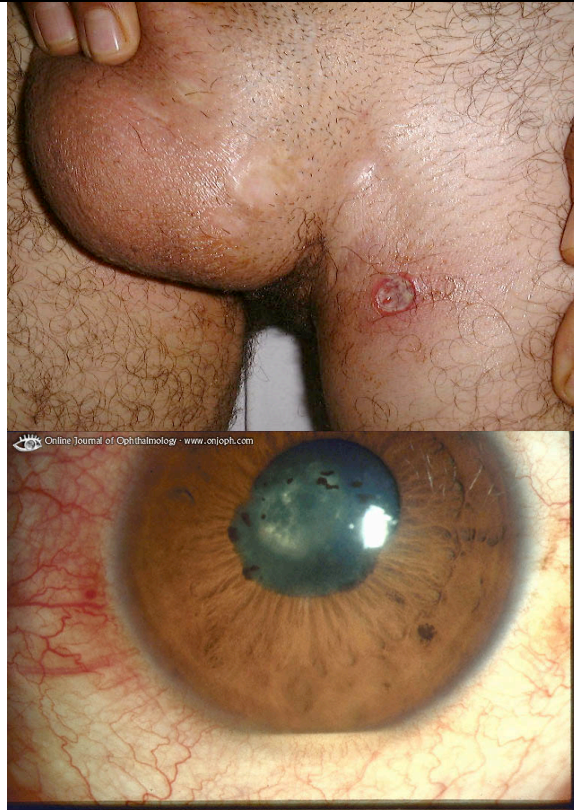


A 25 year old man presented to the department because of a strange lesion in his groin (upper pic) and sore eyes (bottom picture). He had been unwell for a while with sore joints and mouth and has lost some weight. A couple of weeks ago he had noticed that his shins developed some strange bruises.

Describe the top lesion. 1 point
List 3 abnormalities in the bottom picture and what is their cause? 3 points

What is the unifying diagnosis and what blood tests would you do to confirm it? 2 points



*A single well defined ulcer in the left groin.
Injected cornea, uneven pupil, hypopyon= uveitis
Behcet's disease
No bloods- there are no diagnostic test it is a clinical diagnosis:*

Major features

*Recurrent aphthous ulceration of the oral mucous membrane
Skin lesions - Erythema nodosum-like lesions, subcutaneous thrombophlebitis, folliculitis (acnelike lesions), cutaneous hypersensitivity
Eye lesions - Iridocyclitis, chorioretinitis, retinouveitis, definite history of chorioretinitis or retinouveitis*

Genital ulcers

Minor features *Arthritis without deformity and ankylosis
Gastrointestinal lesions characterized by ileocecal ulcers*

Epididymitis

Vascular lesions

Central nervous system symptoms

Diagnosis

Complete - Four major features

Incomplete - (1) 3 major features, (2) 2 major and 2 minor features, or (3) typical ocular symptom and 1 major or 2 minor features

Possible - (1) 2 major features or (2) 1 major and 2 minor features

List 8 other systemic, non traumatic, conditions which can present with a skin ulcer. 4 points

- Arterial insufficiency
- Diabetes Mellitus
- Venus insufficiency
- pyoderma gangrenosum
- Syphilis
- TB/Leprosy
- Trigeminal trophoc syndrome
- Leishmaniasis
- Drug reactions e.g. methotraxate
- Skin secondaries
- Calciphylaxis