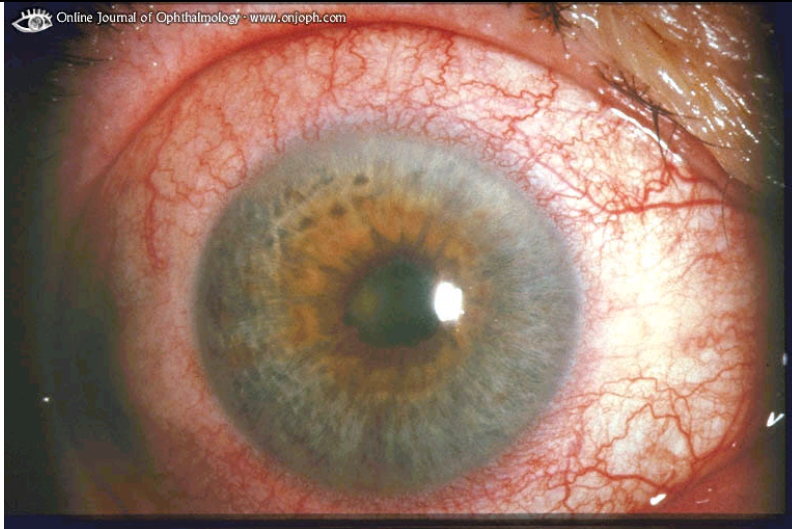
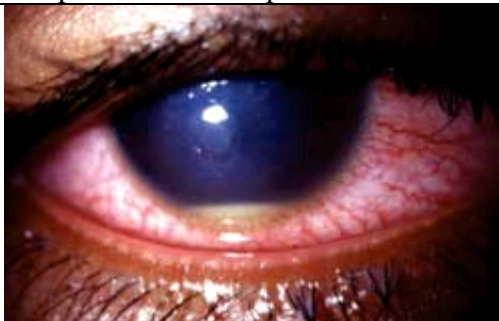


Painful red eye,  
pain worse on  
light.  
Name the  
condition and the  
treatment.  
2 points



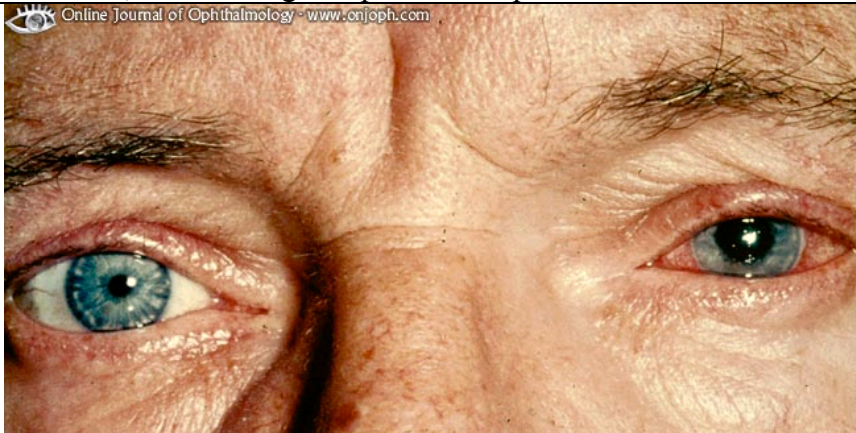Iritis/uveitis, Rx with topical steroid drops

What does the  
picture show and  
what is the  
condition  
causing it? 1  
points  
How would you  
dispose of the  
pt? 1 point



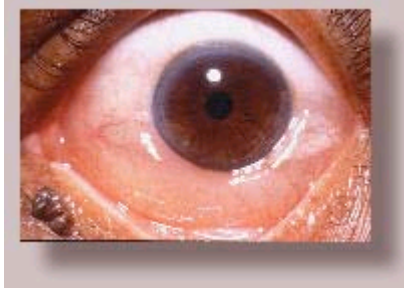
Hypopyon, bacterial keratitis; refer for urgent ophthalmic opinion

Painful L eye.  
Name the  
condition and 4  
drugs which  
could be used to  
treat this in  
A&E.  
3 points



*Acute angle closure glaucoma- topical b-blockers, topical a-agonists, pilocarpine drops and acetazolamide IV, analgesia, IV mannitol*

Very itchy, watering eye  
for last few hours no  
other symptoms. Pt  
noticed this swelling and  
is concerned. What is it?  
Which part of PMH  
would be important ?  
How would you treat  
this? 3points



*Conjunctival oedema/chemosis; ask for H/O allergies esp hay fever; antihistamine eye drops*

