

Radiology

These 2 radiographs show the same injury.

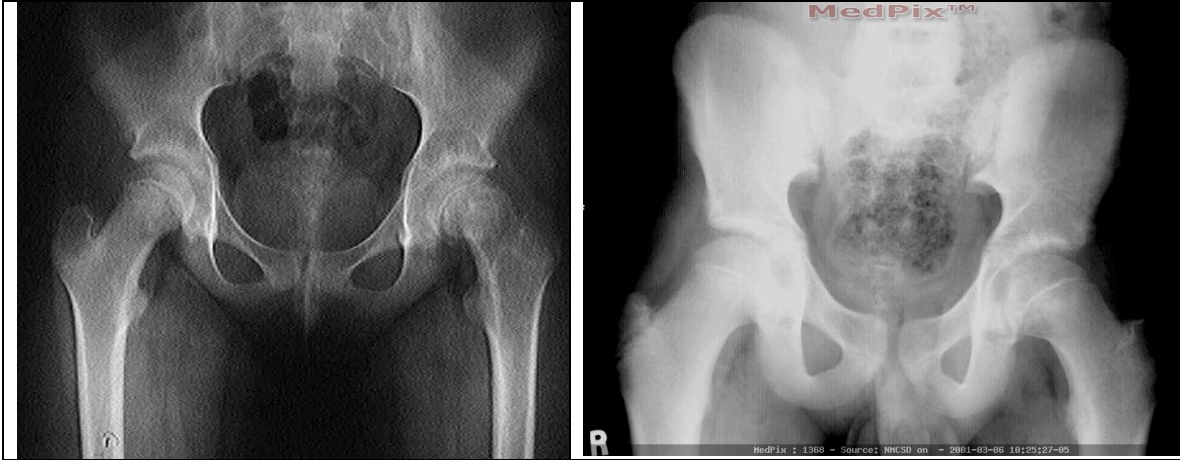
Name the injury 1 point

How do you tell- 1 point

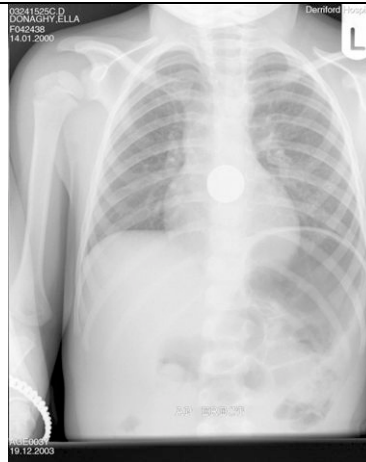What age group does it typically affect? - 1 point

Why is the injury on the left rarer than the right? 1 point

What is the treatment in A&E and definitive? 1point



What are the 2 most likely places for the coin to be in. 1point
What makes you say that? 1 points



This patient came to A&E with this rather odd rash on her trunk. You noticed that her breathing is a bit more laboured than you'd expect a 30 year old healthy female to be and she has fine crackles all over her lungs. Describe the X-ray- 1point
What is the disease? 1 point

