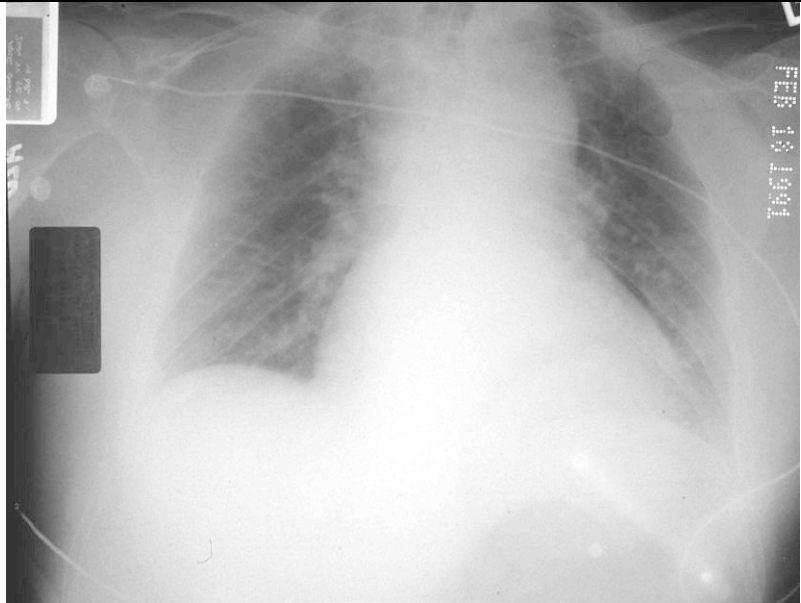


This pt was brought in from an RTC. Name 5 abnormalities on this X-ray, what is the diagnosis? 3points



Mane 2 other abnormalities associated with this injury which can be visible on a chest X-ray. 2 points

This pt had a large amount of blood noted in his trachea on intubation. Apart from all the iatrogenic bits, name 2 abnormalities on this X-ray. 2 points
Following chest drain insertion there was a very large air leak. What is the likely diagnosis. 1 point
How cloud you confirm that and how would you treat the hypoxia in this case? 2 points

