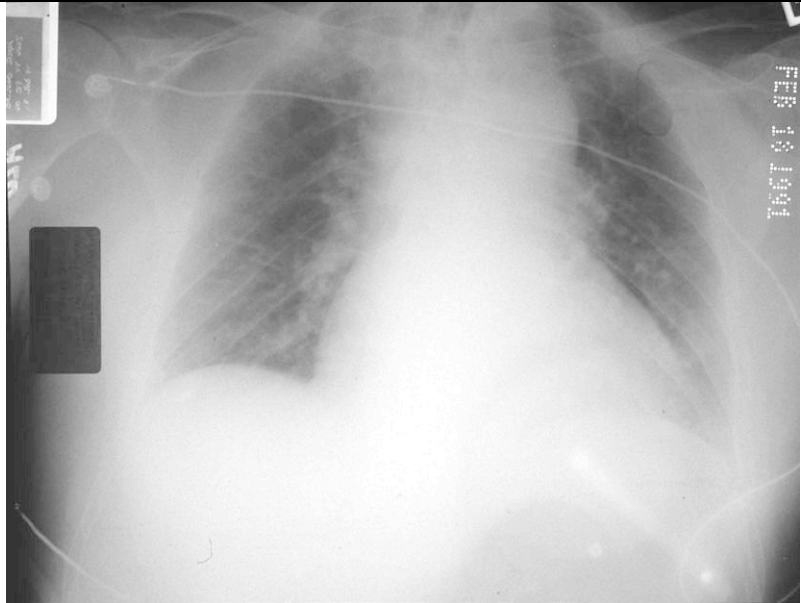


This pt was brought in from an RTC.
Name 5 abnormalities on this X-ray, what is the diagnosis?
3points

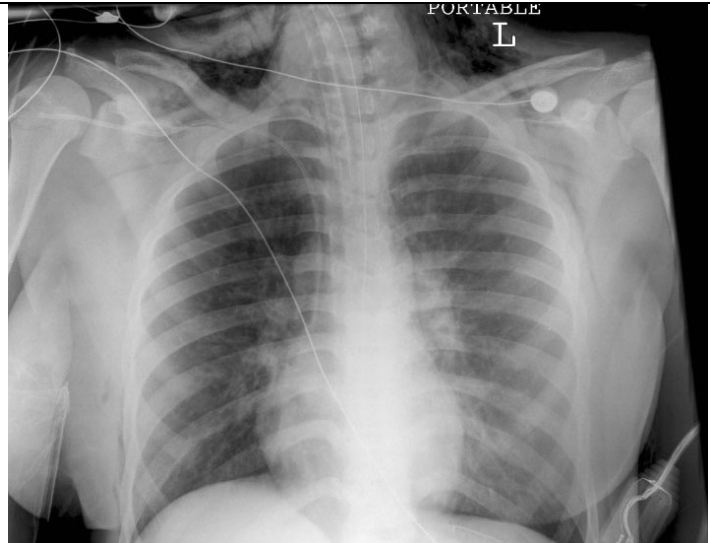


Mediastinal widening
Deviation of trachea to the R
Obliteration of aortic knuckle
L Haemothorax
Obliteration of the AP window (the space between L pulmonary artery and the Aorta)
Extra ½ point for inadequate X-ray- apices not visible
Traumatic aortic rupture

Name 2 other abnormalities associated with this injury which can be visible on a chest X-ray. 2 points

Depression of L main stem bronchus
Deviation of oesophagus (NGT)
Widened paratracheal stripe
Widened paraspinal interfaces
Presence of pleural/apical cap
Fractures 1st/2nd rib +/- scapula

This pt had a large amount of blood noted in his trachea on intubation. Apart from all the iatrogenic bits, name 2 abnormalities on this X-ray. 2 points
Following chest drain insertion there was a very large air leak. What is the likely diagnosis. 1 point
How could you confirm that and how would you treat the hypoxia in this case? 2 points



Pneumomediastinum and surgical emphysema
Tracheo-bronchial tree injury
Bronchoscopy and reposition ETT into the intact bronchus.

