

Name 10 features associated, directly or indirectly, with liver disease which can be found in the hand. 10

Anaemia

Jaundice

Bruising

Palmar erythema

Dupitrien's contracture

Leuconychia

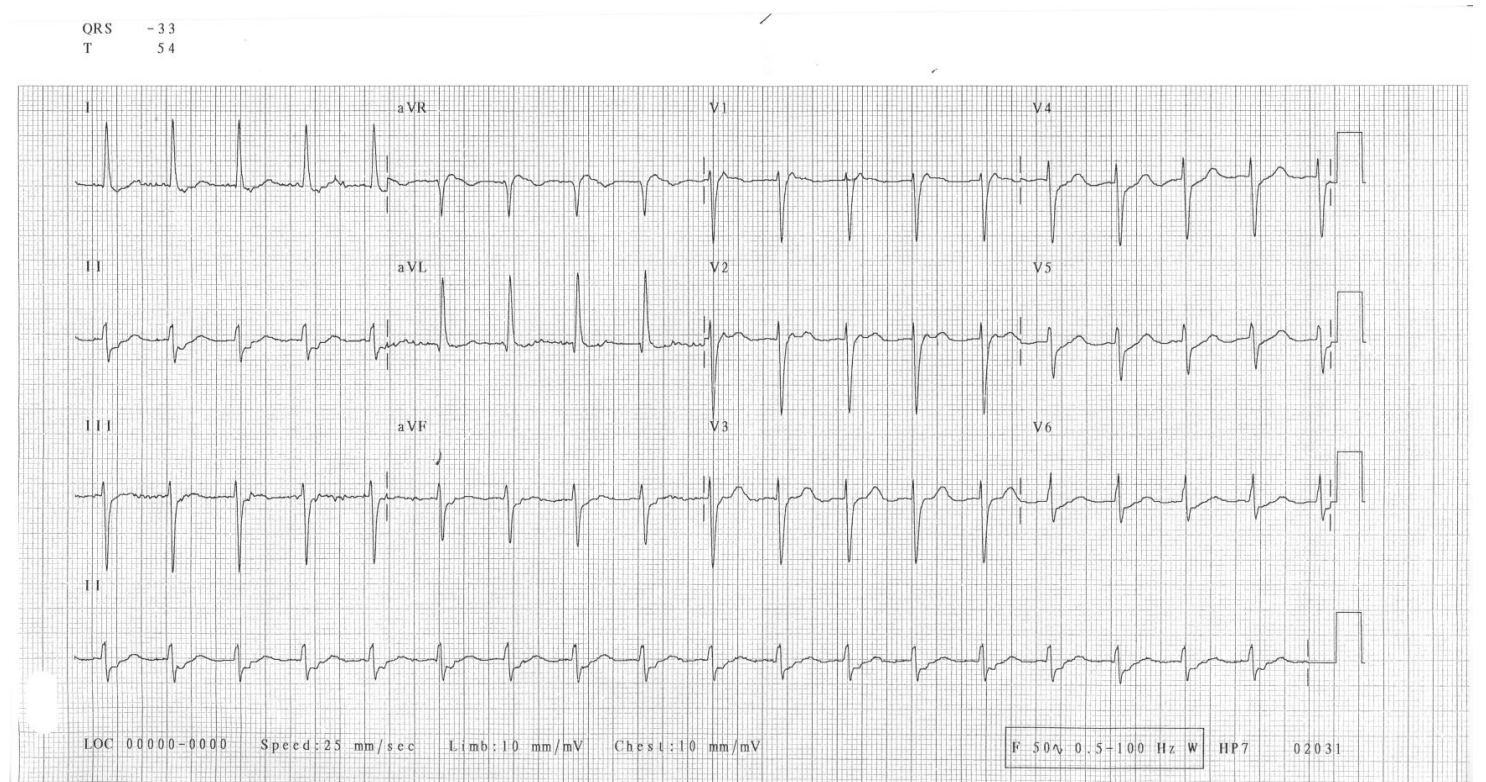
Tremor

Tattoos

Clubbing

Spider naevi

Describe this ECG- 2 points



*Junctional Tachycardia ( ½ point for supraventricular), Rate of 115 ( 110-120), Left Axis Deviation, retrograde p waves buried within QRS*

According to the APLS SVT algorithm what is the first treatment in children with SVT? 1 point  
Which 6 drugs can be used to treat SVT? 6 points

- Vagal manoeuvre*
- Adenosine 50/100/250 mcg/kg*
- Verapamil*
- Digoxin*
- Propranolol 50mcg/kg*
- Flecainide 2mg/kg*
- Amiodarone 5mg/kg*

*EXTRA ½ POINTS FOR THE DOSES*

Which of the above drugs should be avoided in children under 1?

*Verapamil*

A 3 year old boy present to your department because his parents noticed him limping over the last 3 days. There is no history of trauma and he had been walking and running around normally until now. Name 10 acquired, non traumatic, causes of a limp in a child which are localised to the leg- 5 points

*Cellulitis*  
*Septic arthritis*  
*Osteomyelitis*  
*Perthe's*  
*Irritable hip*  
*Juvenile RA*  
*Neoplasms*  
*Warts*  
*Rickets*  
*Scurvy*  
*Polio*

A 2 year old boy presents to A&E with 1 day H?O NWB on his L foot. There is a vague history of possible fall yesterday at grandparents but he was walking well all day until developing a slight limp in the evening. He has chicken pox all over his body, temperature of 38.4 °C, tachycardia of 140 regular. He is covered in ch. Pox rash and slightly flushed on his face. He is refusing to put any wt on his L leg. On close examination he appears to be tender just above his lateral malleolus with a slight swelling there. His hip, knee etc appear to be fine. List 3 investigations which are most likely to give you the diagnosis? 3 points

*X-ray, USS, bone scan, ½ point for MRI or CT*

Give 2 most likely diagnosis 2 points

*Fracture distal fibula, osteomyelitis fibula- there is an association between ch pox and osteomyelitis/septic arthritis*