

## Emergency Approach to Red Eye

It is difficult to create a single flow chart that encompasses all aspects of red-eye, but the detail outlines the things that should be asked and looked for with differentials as you go along. After a table summarises the different features of each major condition, followed by some pictures.

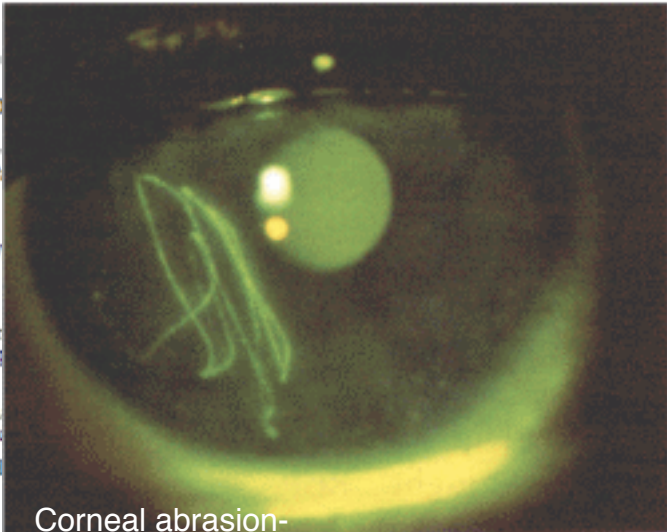
Detail		Likely causes
<b>History</b>	Trauma or FB	Corneal abrasion, eye perforation, FB
	Pain	acute narrow angle glaucoma, scleritis, uveitis, endophthalmitis, abrasion, ulcer (bacteria, fungi, viruses, exposure-VII palsy, autoimmune-RhA, neurotrophic)
	Blurred vision	Mostly abrasions or most more severe eye disease
	Photophobia	Abrasion, iritis
	Haloes	Glaucoma
	Itch	allergic conjunctivitis, blepharitis
	Clear discharge	abrasion, FB, allergic & viral conjunctivitis
	Pus discharge	bacterial conjunctivitis (both eyes) or corneal ulcer (one eye)
	Previous eye disease	iritis, marginal keratitis, dendritic ulcer, endophthalmitis post eye surgery
	Both eyes	allergic & viral conjunctivitis
	Contact lens use	bacterial corneal infections
	Other illness	anterior uveitis secondary to eg ulcerative colitis/ Crohns/Ank Spond. Urethral discharge with Reiters syndrome, gonorrhoea, Chlamydia. Previous viral URTI with viral conjunctivitis
	Drug history	drug reaction

## Emergency Approach to Red Eye

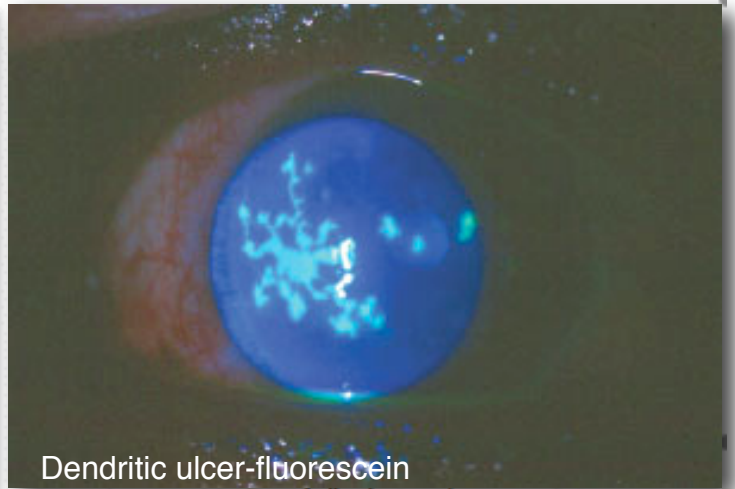
Detail		Likely causes
<b>Exam</b>	Both eyes involved	allergic, viral and bacterial
	Discharge seen as above	
	Cornea clear	allergic & viral conjunctivitis, iritis,
	Cornea cloudy	spot-ulcer, general-glaucoma
	Anterior chamber	shallow in narrow angle glaucoma, pus (hypopyon) cells, and flare (visible light beam) in iritis/scleritis, blood (hyphaemia)penetrating/blunt trauma
	Conjunctiva-general injection	allergic, viral & bacterial conjunctivitis, corneal abrasion, ulcer and FB
	Conjunctiva sectoral injection	Episcleritis (superficial blood vessels), Scleritis (deep immoveable blood vessels and risk of perforation)
	Conjunctiva-ciliary injection (ring around cornea)	iritis, acute glaucoma.
	Sub-conjunctival blood	mostly insignificant no specific treatment required. If recurrent=hypertension/bleeding diathesis
	Pupil mishappen and unreactive	iritis, acute narrow angle glaucoma,
	Evert eyelids	FB's, cobblestone-allergic/bacterial conjunctivitis, grey rice-grains=viral conjunctivitis
	Fluorescein	abrasions, ulcers, dendritic, widespread with contact lens/alkali burns
	Abnormal vitrous/retina on slit lamp	Posterior uveitis/endophthalmitis
	Intraocular pressure	normal <21mmHg, >40mmHg=glaucoma

If the redevye is bilateral, with NO blurred vision, no pain, and a discharge or related to abrasion or FB, then ED can manage it. If not refer to Ophthalmology, urgent if ?ulcer, glaucoma, iritis, endophthalmitis

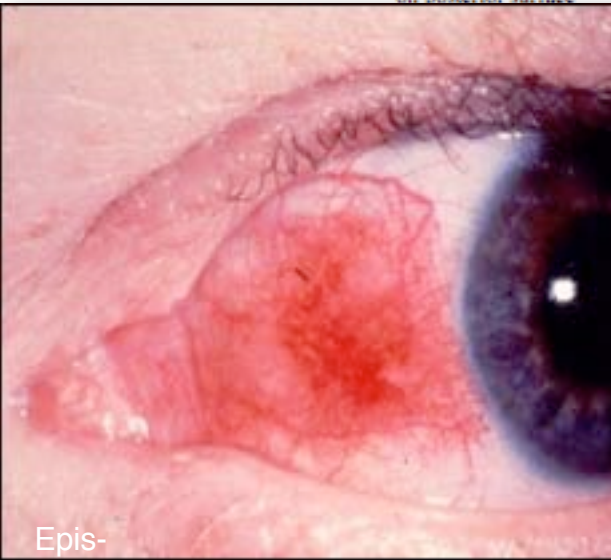
# Emergency Approach to Red Eye



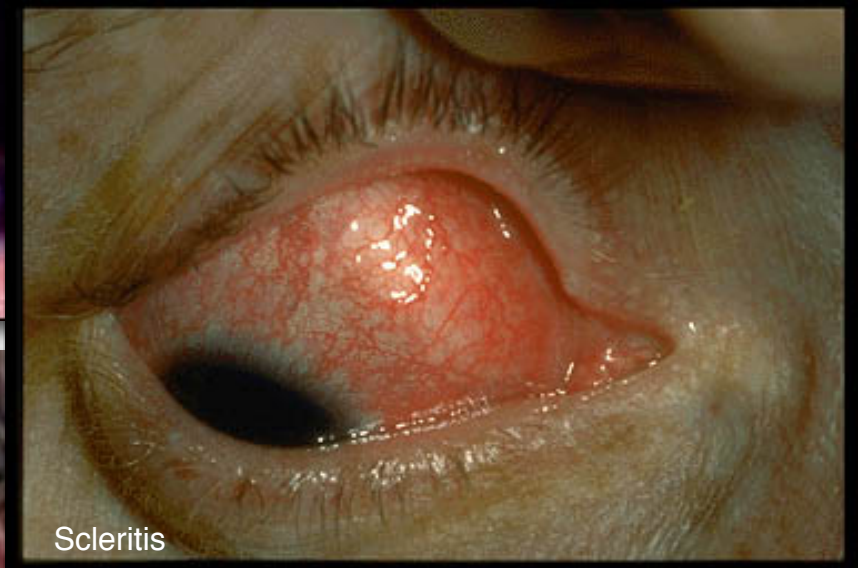
Corneal abrasion-fluorescein



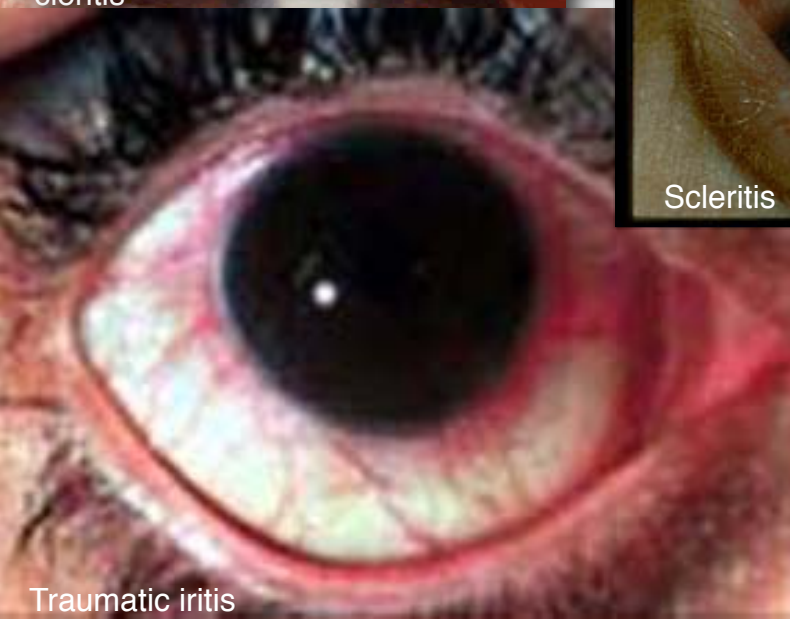
Dendritic ulcer-fluorescein



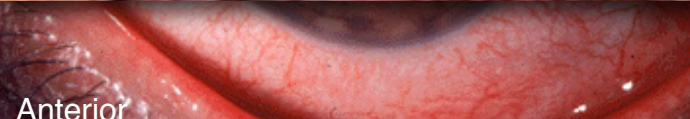Episcleritis



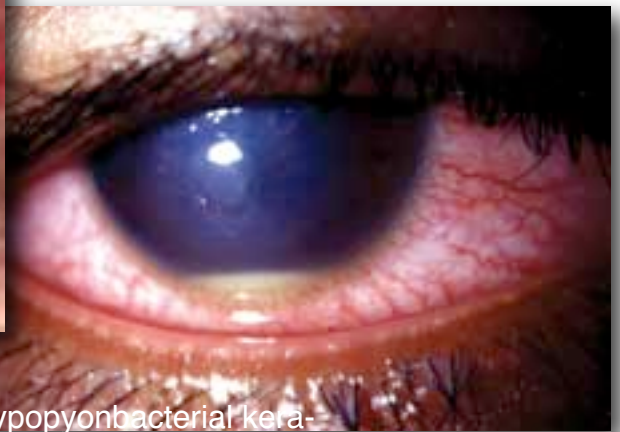
Scleritis



Traumatic iritis



Anterior uveitis



Hypopyon bacterial keratitis

Cloudy	Normal	If corneal injury, may be hazy
Very shallow	Normal depth	Normal depth, may contain blood
Swollen and boggy	Normal	May be obscured by blood or lacerated
Mid-dilated, unreactive	Normal	May be large, normal, small, or irregular
Minimal	Normal	Usually minimal