

The Six Second ECG



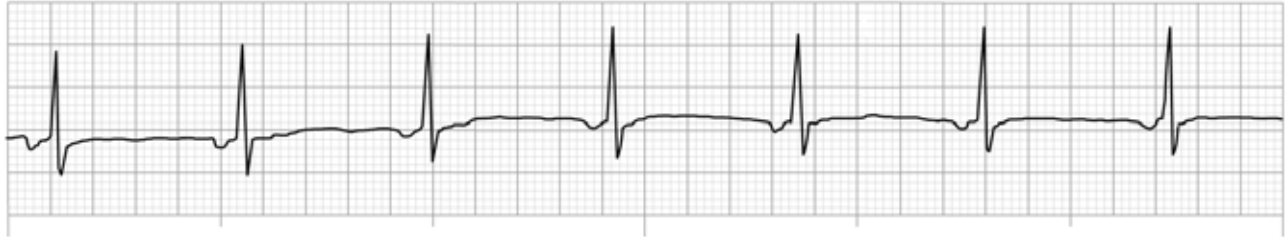ECG Quiz 2A

Version 2.1

The Six Second ECG Quiz 2A (version 2.1)

Please answer the following questions by circling the correct answer on the accompanying answer sheet. **Please do not write on this test booklet.** All rhythms are six second ECGs from lead II.

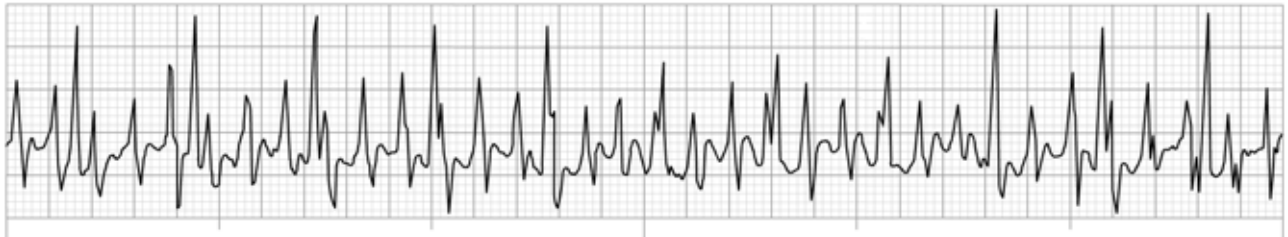
Question 1



This ECG rhythm is called:

- a) Sinus bradycardia
- b) Ectopic atrial rhythm
- c) Sinus rhythm with aberrant intraventricular conduction
- d) Accelerated junctional rhythm

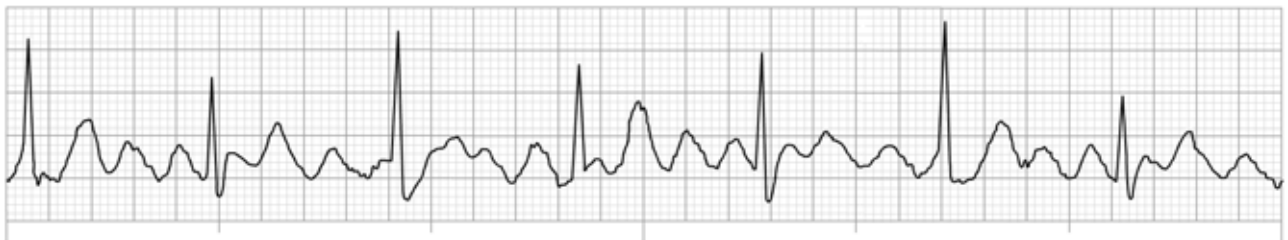
Question 2



This ECG rhythm is called:

- a) Supraventricular tachycardia (SVT)
- b) Movement artifact
- c) Atrial fibrillation
- d) Atrial flutter

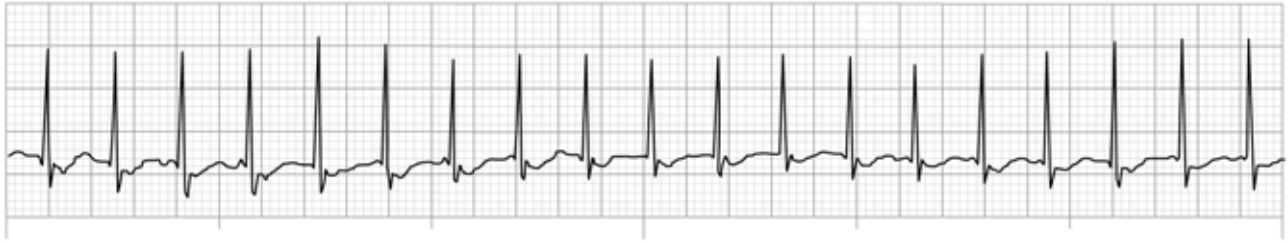Question 3



This ECG rhythm is called:

- a) Atrial fibrillation
- b) Sinus rhythm with movement artifact
- c) Atrial flutter with 2:1 ventricular response
- d) Atrial flutter with 4:1 ventricular response

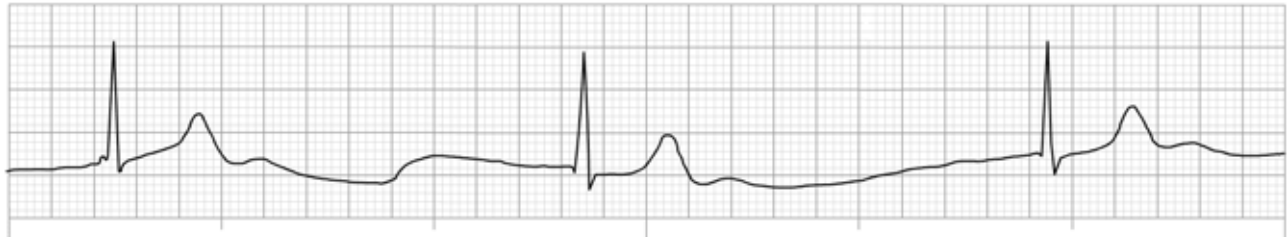
Question 4



This ECG rhythm is called:

- a) Sinus tachycardia
- b) Atrial fibrillation with rapid ventricular response
- c) Junctional tachycardia
- d) Ventricular tachycardia

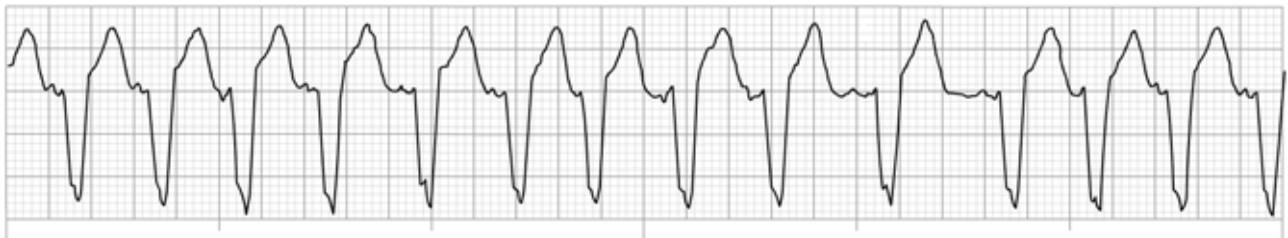
Question 5



This ECG rhythm is called:

- a) Sinus arrhythmia
- b) Junctional rhythm
- c) Junctional bradycardia
- d) Sinus bradycardia

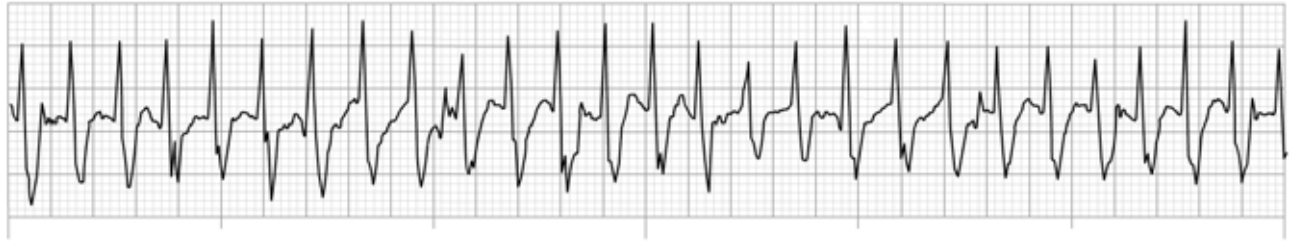
Question 6



This ECG rhythm is called:

- a) Multifocal atrial tachycardia
- b) Sinus tachycardia
- c) Junctional tachycardia
- d) Ventricular tachycardia

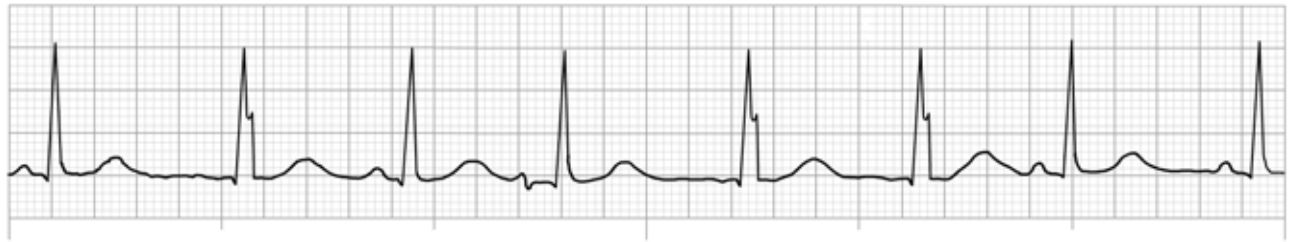
Question 7



This ECG rhythm is called:

- a) Junctional tachycardia
- b) Supraventricular tachycardia (SVT)
- c) Sinus tachycardia
- d) Atrial fibrillation with fast ventricular response

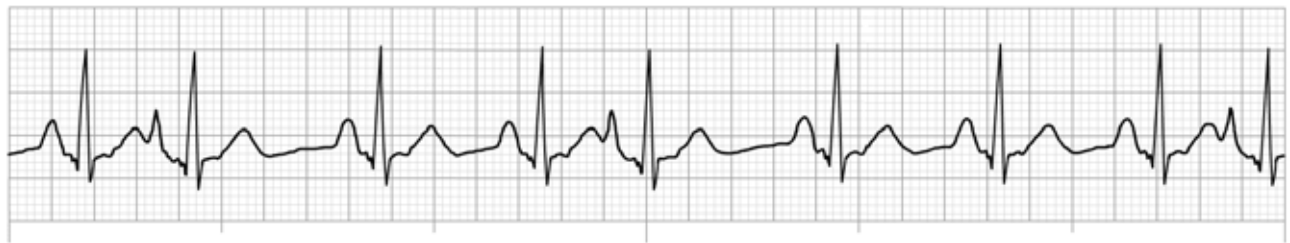
Question 8



This ECG rhythm is called:

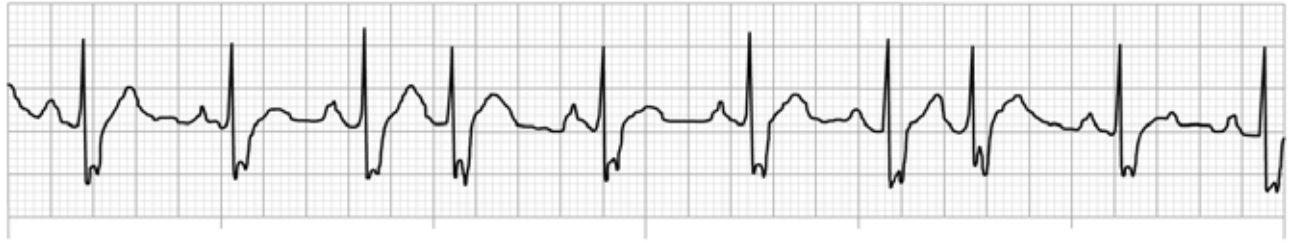- a) Sinus arrhythmia
- b) Wandering pacemaker
- c) Sinus rhythm
- d) Atrial fibrillation

Question 9



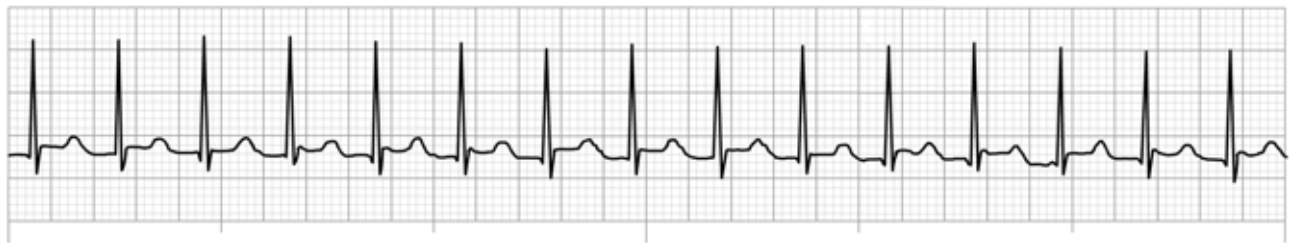This ECG rhythm is called:

- a) Sinus arrhythmia
- b) Atrial fibrillation with ectopic atrial beats
- c) Sinus tachycardia with premature ventricular complexes (PVCs)
- d) Sinus rhythm with premature atrial complexes (PACs)

Question 10

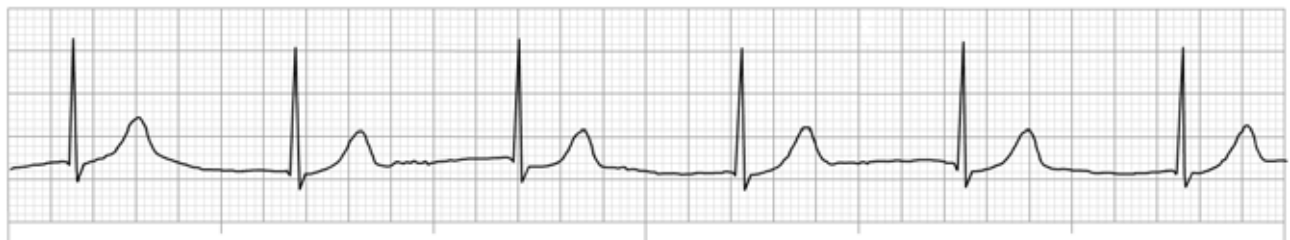
This ECG rhythm is called:

- a) Sinus rhythm with aberrant intraventricular conduction and two PVCs
- b) Atrial fibrillation with aberrant intraventricular conduction
- c) Sinus rhythm with two PJs with aberrant intraventricular conduction
- d) Sinus arrhythmia with aberrant intraventricular conduction

Question 11

This ECG rhythm is called:

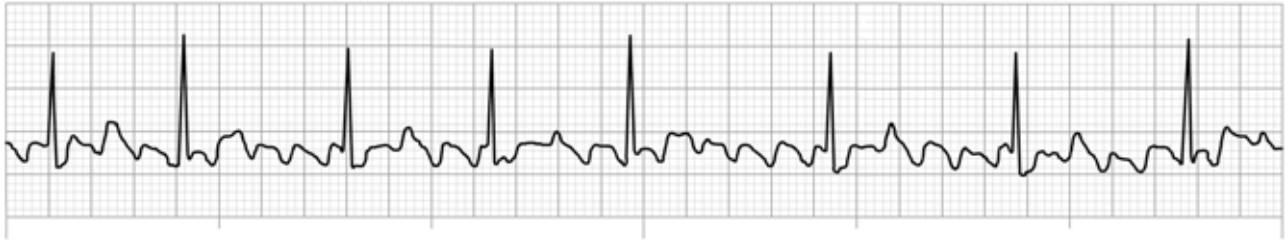
- a) Atrial fibrillation with rapid ventricular response
- b) Accelerated junctional rhythm
- c) Sinus tachycardia
- d) Junctional tachycardia

Question 12

This ECG rhythm is called:

- a) Wandering pacemaker
- b) Sinus rhythm
- c) Junctional rhythm
- d) Accelerated idioventricular rhythm

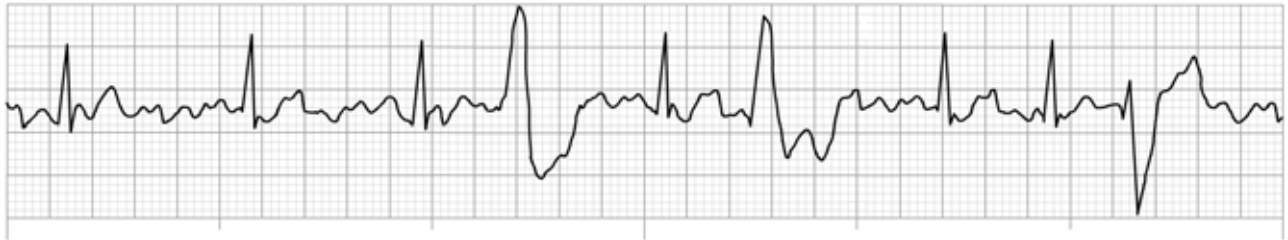
Question 13



This ECG rhythm is called:

- a) Atrial flutter with variable ventricular response
- b) Sinus rhythm with PACs
- c) Atrial fibrillation with fast ventricular response
- d) Sinus arrhythmia

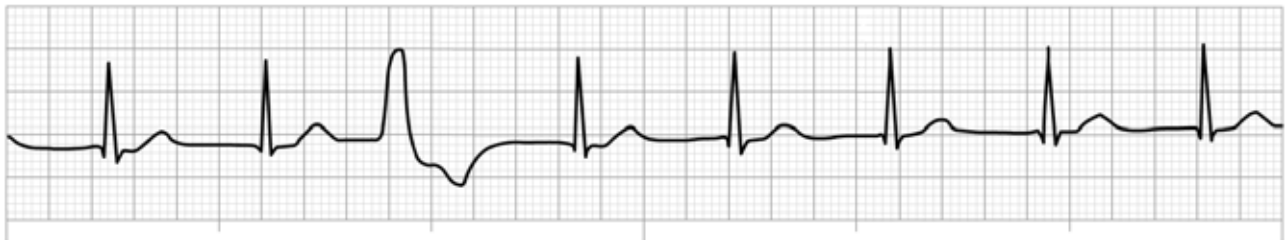Question 14



This ECG rhythm is called:

- a) Atrial flutter with multifocal PVCs
- b) Atrial fibrillation with multifocal PVCs
- c) Sinus bradycardia with multifocal PVCs
- d) Accelerated junctional rhythm with PACs

Question 15



This ECG rhythm is called:

- a) Sinus rhythm with a PVC
- b) Sinus rhythm with a PAC
- c) Accelerated junctional rhythm with a PVC
- d) Junctional tachycardia with a PVC